

Planning and use of oncoplastic surgery for breast cancer

A. A. Samusieva^{1,2}, R. V. Liubota², V. V. Zaichuk², O. V. Ponomarova^{1,3}, I. I. Liubota³

¹Shupyk National Healthcare University of Ukraine, Kyiv

²Bogomolets National Medical University, Kyiv

³Kyiv municipal clinical cancer center

Today, breast conserving surgery among women with different stages of breast cancer is increasing. In addition, these operations do not differ in oncological radicality and do not show differences in relation to survival compared to mastectomy, but their cosmetic and psychological benefits are significant. In search of a balance between the risk of local recurrence and cosmetic results in surgical interventions in breast cancer, new surgical variants were introduced – a combination of *breast conserving surgery* with plastic surgery, so-called oncoplastic surgery.

Oncoplastic surgery has been widely developed in the surgical treatment of breast cancer in the last decade. In oncoplastic breast surgery, the tumors of the upper-inner quadrant of the breast are problematic and require more attention of the surgeon. In these cases the size and location of the tumor are two important factors for the post-operative cosmetic outcome.

In this article we introduce a modified dermoglandular rotation flap technique, which can be applied for relatively large tumors of inner quadrant of the breast without surgery of the contralateral breast for symmetrical effect. With this technique, a larger breast tumor could be removed without compromising the breast appearance.

An important aspect of *breast conserving surgery* is preoperative evaluation of the clinical and biological features of the tumor as well as the morphological aspects of tumor allow the surgeon to make a decision if a conservative is possible and select the most effective oncoplastic surgical technique. Oncoplastic techniques may improve cosmetic view and patient satisfaction without compromising the oncological outcomes, which is confirms the clinical utility of this approach to the surgical management of patients with breast cancer.

The article also presents clinical cases – 46 years old patient with left breast cancer (stage I cT1N0M0 pT1N0M0) and a patient of 42 years old with right breast cancer (stage I cT1NXM0 pT1N0M0) in the treatment of which the described technique was applied.

Keywords: *breast cancer, breast conserving surgery, upper-inner quadrant.*

Планування та особливості виконання онкопластичних операцій при раку грудної залози

A. A. Самусєва, Р. В. Любота, В. В. Зайчук, О. В. Пономарьова, І. І. Любота

На сьогодні зростає популярність органозберігальних операцій на грудних залозах серед жінок із ранніми стадіями раку грудної залози. Крім того, ці операції не відрізняються онкологічною радикальністю та не демонструють різниці стосовно показників виживання порівняно з мастектомією, однак їхні косметичні та психологічні переваги є суттєвими. У пошуках балансу між ризиком місцевого рецидиву та косметичними результатами при хірургічних втручаннях при раку грудної залози були запроваджені нові хірургічні варіанти – поєднання органозберігальної операції з методами пластичної хірургії, так звані онкопластичні операції.

За останнє десятиріччя широкого розвитку у хірургічному лікуванні раку грудної залози отримала саме онкопластична хірургія. При онкопластичних операціях на грудній залозі пухлини верхньовнутрішнього квадранта є особливо проблемними і вимагають більшої уваги хірурга. У цьому випадку розмір і розташування пухлини – два важливі фактори для післяопераційного косметичного результату.

У статті представлено модифіковану техніку з використанням дермогландулярного ротаційного клаптя, яка може бути застосована для відносно великих пухлин внутрішнього квадранта грудної залози без хірургічного втручання на контралатеральній грудній залозі для симетризації. Застосування цієї методики дозволяє зберегти грудну залозу при більших розмірах пухлини без шкоди для зовнішнього вигляду грудних залоз.

Важливим елементом органозберігального хірургічного лікування є передопераційне оцінювання клініко-біологічних особливостей та морфологічних аспектів пухлини, що дозволяє хірургу прийняти рішення про можливість консервативного лікування та вибрати найбільш ефективну онкопластичну хірургічну техніку. Онкопластичні операції можуть покращити косметичний ефект та задоволеність пацієнтів без шкоди для онкологічних результатів, що підтверджує клінічну корисність цього підходу до хірургічного лікування пацієнтів з раком грудної залози.

У статті наведено клінічні випадки – пацієнтки 46 років із раком лівої грудної залози (стадія I cT1N0M0 pT1N0M0) та хворої 42 років із раком правої грудної залози (стадія I cT1NXM0 pT1N0M0), у лікуванні яких застосовували описану методику.

Ключові слова: *рак грудної залози, органозберігальні операції, верхньовнутрішній квадрант.*

The priority area of the surgical treatment of breast cancer (BC) today is breast-conserving surgery (BCS), which is no less effective than mastectomies. Overall survival and disease-free survival after a previous BCS are equivalent to mastectomy, but BCS is associated with a higher quality of life for patients, improves psychosocial adaptation after treatment, and satisfaction with relationships or sexual life [1–4, 5].

The history of breast cancer surgery began with mutilating operations, which caused not only physical disorders in patients, but also mental disorders. This led to the impossibility of rehabilitation and social adaptation of such patients [6]. With the development of medicine, the operations caused less traumatizing consequences, but the problem remains relevant today. This is due to the fact that in some cases, in the presence of large size tumor and/or a small volume of the breast, BCS may be contraindicated due to the expected unsatisfactory aesthetic outcomes as a result of deformation. Oncoplastic surgery is especially important for young patients, in which case mastectomy causes an insurmountable psychological barrier and may cause refusal of treatment. Today, there are many options for oncoplastic resections. In modern practice, the term oncoplastic radical resection (OPS – BCS – oncoplastic surgery – breast conserving surgery) is used. For the first time the term «oncoplastic surgery» was proposed by Bostwick III in 1986 [7–9].

This area of surgery has been developed to expand the capabilities of BCS, reduce the number of reoperations and mastectomies, prevent postoperative breast deformities. The selection of wrong BCS technique often causes postoperative deformation of breast. The problem of choosing an appropriate technique for oncoplastic resection leads to mastectomy being more frequently recommended by a doctor. Studies N. Kaur, et al (60 patients) and K.B. Clough, et al. (101 patients) showed that in 5–18% of cases when standard BCS technique was used, the resection margins were positive, which led to an increase in the number of reoperations [10, 11].

The concept of oncoplastic surgery is based on the use of the principles of plastic surgery in the process of reconstructive surgery immediately after wide resection of the breast tumor with adequate margins. The aim of such operations is complete tumor resection and preservation of the natural shape of the breast [12]. Radiation therapy will always be prescribed after oncoplastic resections as well as after standard BCS in patients with invasive breast cancer, regardless of other factors (degree of tumor differentiation, tumor size, lymph node status, etc.), as ([13].

Case Report

Clinical case No.1:

Patient N., 46 years old, the diagnosis: Left breast cancer Stage I cT1N0M0 pT1N0M0.

The patient was treated at the surgical department of the Kyiv Municipal Clinical Cancer Center. Primary data: there is a tumor in the upper-inner quadrant of the left breast up to 2 cm in diameter, it is palpable as firm, moderately mobile, bosselated. Skin symptoms are negative. There are no nodular changes in the right breast. The nipple and areola are without changes. Axillary lymph nodes are elastic and mobile. Other groups of regional lymph nodes are not palpable. The menstrual cycle is saved. Mammography: a tumor in the upper-inner quadrant, 19x12mm in diameter.

Ultrasound: unchanged structure and size of axillary lymph nodes.

It is decided to perform oncoplastic operation to the patient. The preoperative marking was made, see Figures 1 and 2. On January 17, 2018, was performed an operation – oncoplastic resection by the type of reduction mammaplasty on the upper-limb with a V - shaped scar.

Result of pathomorphological study: Invasive ductal carcinoma of the breast, moderately differentiated (G 2), non special type (NST). In the lymph nodes – sinus histiocytosis, lipomatosis.

The tactics of further treatment was discussed at a council with the surgeons, chemotherapists, radiologists

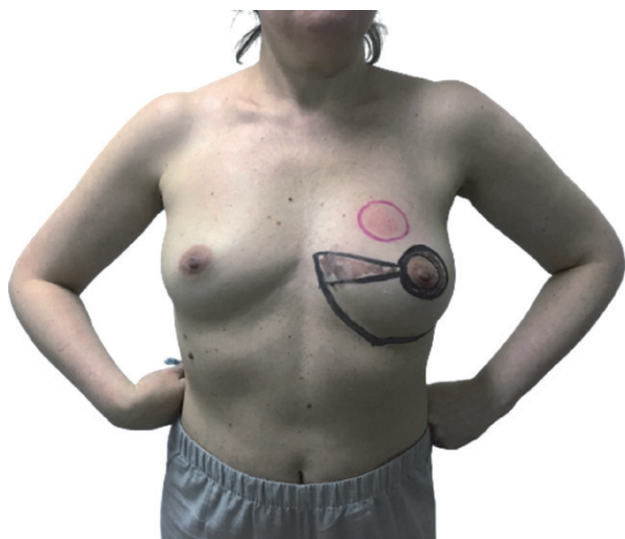


Fig. 1. Preoperative view, clinical case No.1

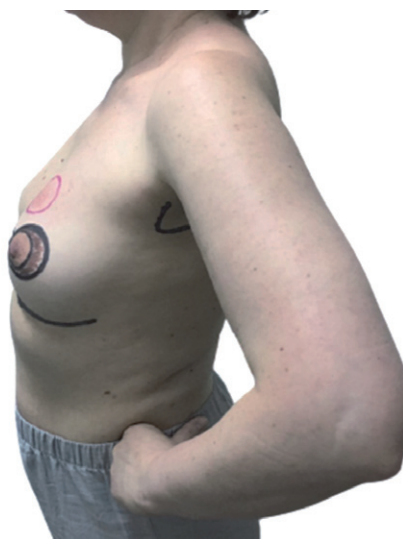

Fig. 2. Preoperative view, clinical case No.1

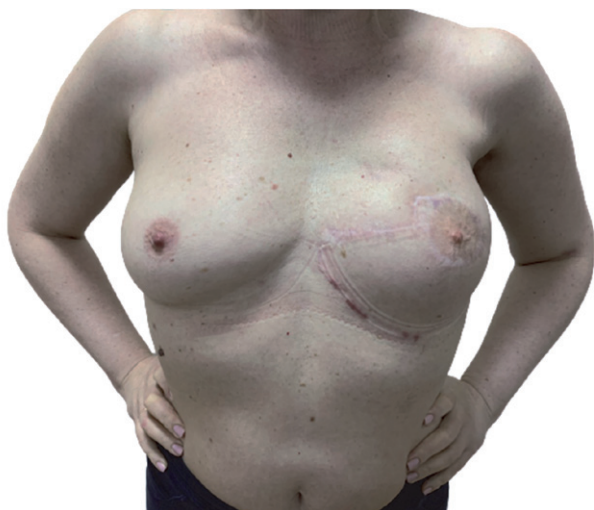

Fig. 3. Postoperative view, clinical case No.1

and diagnosticians. The postoperative course of radiation therapy followed by hormone therapy was recommended to the patient.

Fig. 3, 4 shows a patient 1 year after left breast oncoplastic operation.

Clinical case No. 2:

Patient A., 42 years old, diagnosis-Right breast cancer Stage I cT1NxM0 pT1N0M0.

The patient was treated in the surgical department of the Kyiv Municipal Clinical Cancer Center. Primary data: there is a tumor in the upper-inner quadrant of the right breast up to 1.5 cm in diameter, is palpable as firm, moderately mobile, bosselated. Skin symptoms are negative. There are no nodular changes in the left breast. The nipple and areola are without changes. The right axillary lymph nodes are tightly elastic, up to 1.5 cm in diameter, mobile; the left axillary lymph nodes are elastic and mobile. Other groups of regional lymph nodes are not palpable. The menstrual cycle is saved.

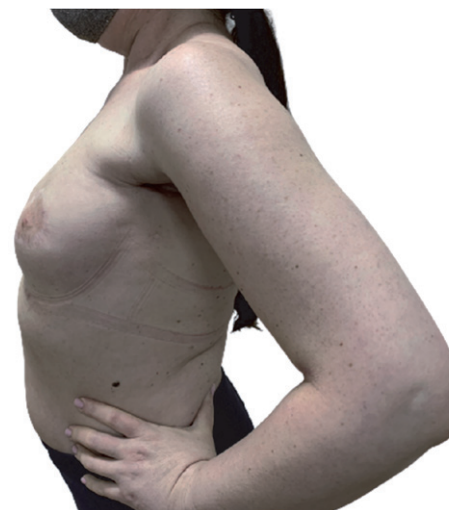

Fig. 4. Postoperative view, clinical case No.1

Mammography: a tumor in the upper-inner quadrant, 15×10 mm in diameter.

Ultrasound: unchanged structure of axillary lymph nodes. Single axillary lymph node 14×8 mm in diameter, suspicious for metastasis.

It is decided to perform oncoplastic operation to the patient. The preoperative marking was made (Fig. 5 and 6). On January 17, 2018, an operation was performed – oncoplastic resection by the type of reduction mammoplasty on the upper – limb with a V - shaped scar.

The result of pathomorphological study: Invasive micropapillary breast carcinoma, moderately differentiated (G 2). In the lymph nodes there is sinus histiocytosis, focal fibrosis.

The tactics of further treatment was discussed at a council with the surgeons, chemotherapists, radiologists and diagnosticians. The adjuvant chemotherapy followed by a postoperative course of radiation therapy and further hormone therapy was recommended to the patient.

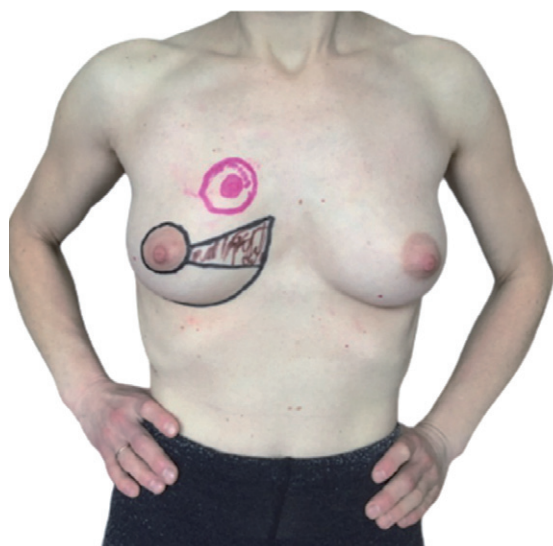


Fig. 5. Preoperative view, clinical case No.2

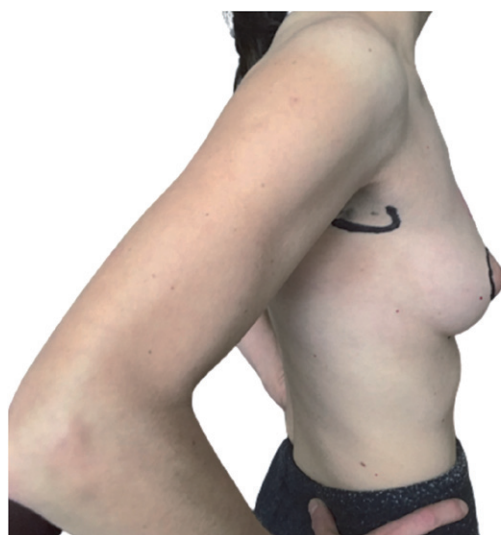

Fig. 6. Preoperative view, clinical case No.2

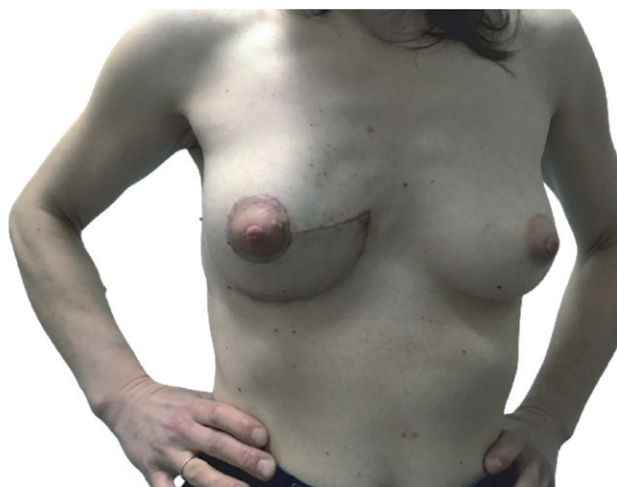


Fig. 7. Postoperative view, clinical case No.2

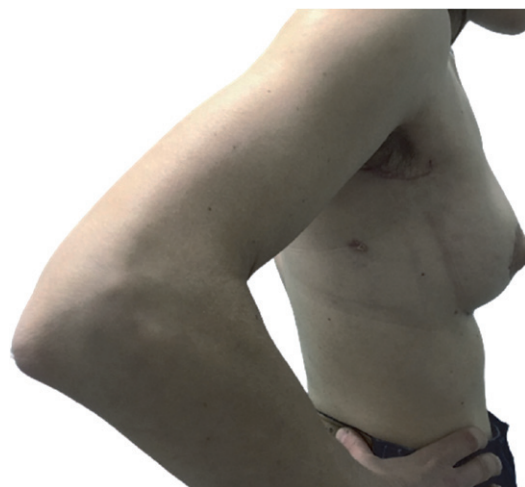

Fig. 8. Postoperative view, clinical case No.2

Fig. 7 and 8 show a patient 3 months after right breast oncoplastic operation. Visually, the breasts differ little in shape; the subsequent symmetrizing operation of the left breast was not required.

Discussion

Oncoplastic resections techniques are more complex than standard BCS techniques and require some skill of the surgeon [14, 15]. Additionally, oncoplastic resections are longer in comparison with the majority of operations of breast cancer, but less traumatic and shorter in duration in comparison to “flap” reconstructions.

Risk factors include smoking, high body mass index, diabetes or metabolic syndrome, etc. All these factors must be considered when surgeon chooses the surgery tactic, since these risks are common to all operations, but more significant in oncoplastic resections and reconstructive operations [16, 17].

Despite the existence of various techniques of oncoplastic operations [18, 19], at present the algorithm of choosing oncoplastic resections in cases with problematic localizations (upper quadrants of the breast) is not standardized. The basic criteria for choosing a resection technique are the location and size of the tumor, the estimated volume of resected glandular tissue and the complexity of the operation [16, 20]. The available techniques for cases with such localization of tumor are described in Table.

Operations on breast with tumor in the upper-inner quadrant are a complex problem due to the small volume of the tissue, proximity of the axilla. A simple rotation of the gland tissues in order to fill the tissue defect that arose after resection of the sector with a tumor in the upper-inner quadrant of the breast leads to the rotation of the nipple-areola complex medially and upwards, which causes a seri-

ous cosmetic defect [21–23]. The interest in solving this problem prompted us to review the techniques of oncoplastic resections for tumors of the upper-inner quadrant of the breast.

Operation options

One possible option for oncoplastic resection in cases with localization of tumor in upper-inner quadrant of the breast is dermoglandular triangular rotation flap (24–26).

Indications:

- BC DCIS, T1-2N0-1M0 or yT3N0-1M0;
- Monocentric tumor;
- Slow or moderate tumor growth rate;
- Negative resection margins;
- The ratio of the size of the tumor to the size of the breast, which allow radical resection of the tumor.

Contraindications:

- BC LCIS, T3-4N2-3M0-1;
- Multicentric tumor;
- Positive tumor margins;
- Inability to conduct a postoperative course of radiation therapy;
- Tumor progression after neoadjuvant chemotherapy.

A relative contraindication can be the presence of mutations in the *BRCA 1* and *BRCA 2* genes.

Preoperative preparation

Mammography and ultrasound examination of the breast and regional lymphatic nodes are routinely performed, if necessary, MRI of the breast can be performed. The planning of the operation is carried out step by step; before the operation the surgeon makes markup of the incision lines, which allows to correctly plan the operation and visually demonstrate the future scar lines to the patient. In addition, the scars on the skin of the breast will influence the choice of incisions.

Oncoplastic resection techniques for tumors located in upper breast quadrants

Breast quadrant	Resection technique
Top-inner	Round block, S-technique, lower-limb, upper / lower-limbs
The border of the upper	Round block, S-technique, lower-limb, Batwing
Top-outer	Round block, S-technique, lower-limb, thoracodorsal flap.

Technique

Intraoperative incision is made at the boundary of internal quadrants of the breast, then tumor sector is removed subcutaneously. After examining the margins of the resection and getting the negative margins the surgeon makes an additional incision in the inferior-inner quadrant. The pyramidal area which is formed in the lower-internal quadrant of the breast (shown in brown on Figure1) is de-epithelized to replace the formed defect later. Then the incision is extended along the submammary fold in the direction of the axillary region. The defect is closed by rotation of the dermatoglandular flap from the inferior-inner quadrant of the breast. Then, lymphadenectomy is performed from a separate skin incision in the axillary region.

CONCLUSIONS

According to the modern principles of breast surgery, plastic surgery techniques complement primary oncologi-

cal operations. All of this is aimed at improving the aesthetic results and psychosocial rehabilitation of patients. The advantage of this technique is the relative ease of implementation, maintaining a good blood supply in the flap, which minimizes trophic complications in the postoperative period. Moreover, symmetrizing surgery of the contralateral breast is rarely needed after this oncoplastic operations. The disadvantage of this technique is the length of the postoperative scar, which in some cases can reach to the décolleté.

Data Availability

No data were used to support this manuscript.

Conflicts of Interest

All authors declared that there are no conflicts of interest such as financial interests, affiliations, or personal interests or beliefs that could be perceived to affect the objectivity or neutrality of the manuscript.

Information about the authors

Samusieva Anastasiia A. – MD, PhD-student, Department of Oncology, Shupyk National Healthcare University of Ukraine, Kyiv, Assistant of Professor, Department of Oncology, Bogomolets National Medical University, Kyiv; tel.: (098) 835-38-07. *E-mail: a_samusieva@yahoo.com*

ORCID: 0000-0003-2222-1683

Liubota Roman V. – MD, Assistant of Professor, Department of Oncology, Bogomolets National Medical University, Kyiv
ORCID: 0000-0002-0278-7893

Zaichuk Vitalii V. – MD, PhD, Associate Professor, Department of Oncology, Bogomolets National Medical University, Kyiv
ORCID: 0000-0001-9311-7221

Ponomarova Olga V. – MD, PhD, Head of Chemotherapy Department N1, Kyiv Municipal Clinical Cancer Center; Associate Professor, Department of Oncology, Shupyk National Healthcare University of Ukraine, Kyiv
ORCID: 0000-0003-3508-6687

Liubota Iryna I. – MD, Chemotherapist, Kyiv Municipal Clinical Cancer Center
ORCID: 0000-0002-3620-8685

Відомості про авторів

Самусєва Анастасія Андріївна – аспірантка, кафедра онкології, Національний університет охорони здоров'я України імені П.Л. Шупика, м. Київ, асистентка, кафедра онкології Національного медичного університету імені О.О. Богомольця, м. Київ; тел.: (098) 835-38-07. *E-mail: a_samusieva@yahoo.com*

ORCID: 0000-0003-2222-1683

Любота Роман Вікторович – асистент, кафедра онкології, Національний медичний університет імені О.О. Богомольця, м. Київ
ORCID: 0000-0002-0278-7893

Зайчук Віталій Володимирович – доцент, кафедра онкології, Національний медичний університет імені О.О. Богомольця, м. Київ
ORCID: 0000-0001-9311-7221

Понюмарьова Ольга Володимирівна – завідувачка, хіміотерапевтичне відділення № 1, КНП «Київський міський клінічний онкологічний центр»; доцент, кафедра онкології, Національний університет охорони здоров'я України імені П.Л. Шупика, м. Київ

ORCID: 0000-0003-3508-6687

Любота Ірина Ігорівна – хіміотерапевт, КНП «Київський міський клінічний онкологічний центр»
ORCID: 0000-0002-3620-8685

REFERENCES

- Huang J, Chagpar A. Factors associated with decision to undergo contralateral prophylactic mastectomy versus unilateral mastectomy. *Am J Surg.* 2019;218(1):170-4. doi: 10.1016/j.amjsurg.2018.11.040.
- Anderson C, Islam JY, Elizabeth Hodgson M, Sabatino SA, Rodriguez JL, Lee CN, Sandler DP, Nichols HB. Long-Term Satisfaction and Body Image After Contralateral Prophylactic Mastectomy. *Ann Surg Oncol.* 2017;24(6):1499-506. doi: 10.1245/s10434-016-5753-7.
- Lizarraga IM, Schroeder MC, Jatoti I, Sugg SL, Trentham-Dietz A, Hoeth L, et al. Surgical Decision-Making Surrounding Contralateral Prophylactic Mastectomy: Comparison of Treatment Goals, Preferences, and Psychosocial Outcomes from a Multicenter Survey of Breast Cancer Patients. *Ann Surg Oncol.* 2021;28(13):8752-65. doi: 10.1245/s10434-021-10426-y.
- Jagsi R, Hawley ST, Griffith KA, Janz NK, Kurian AW, Ward KC, et al. Contralateral Prophylactic Mastectomy Decisions in a Population-Based Sample of Patients With Early-Stage Breast Cancer. *JAMA Surg.* 2017;152(3):274-82. doi: 10.1001/jamasurg.2016.4749.
- Huang J, Chagpar A. Active Participation in Decision-Making in Contralateral Prophylactic Mastectomy for Patients With Breast Cancer. *J Surg Res.* 2019;242:129-35. doi: 10.1016/j.jss.2019.04.037.
- Banks WM. A brief history of the operations practised for cancer of the breast. *Br Med J.* 1902;1(2140):5-10. doi: 10.1136/bmj.1.2140.5.
- Crown A, Wechter DG, Grumley JW. Oncoplastic Breast-Conserving Surgery Reduces Mastectomy and Postoperative Re-excision Rates. *Ann Surg Oncol.* 2015;22(10):3363-8. doi: 10.1245/s10434-015-4738-2.
- Wijgman DJ, Ten Wolde B, van Groesen NR, Keemers-Gels ME, van den

- Wildenberg FJ, Strobbe LJ. Short term safety of oncoplastic breast conserving surgery for larger tumors. *Eur J Surg Oncol.* 2017;43(4):665-71. doi: 10.1016/j.ejso.2016.11.021.
9. Nanda A, Hu J, Hodgkinson S, Ali S, Rainsbury R, Roy PG. Oncoplastic breast-conserving surgery for women with primary breast cancer. *Cochrane Database Syst Rev.* 2021;10(10):CD013658. doi: 10.1002/14651858.CD013658.pub2.
10. Kaur N, Petit JY, Rietjens M, Maffini F, Luini A, Gatti G, et al. Comparative study of surgical margins in oncoplastic surgery and quadrantectomy in breast cancer. *Ann Surg Oncol.* 2005;12(7):539-45. doi: 10.1245/ASO.2005.12.046.
11. Clough KB, Lewis JS, Couturaud B, Fitoussi A, Nos C, Falcou MC. Oncoplastic techniques allow extensive resections for breast-conserving therapy of breast carcinomas. *Ann Surg.* 2003;237(1):26-34. doi: 10.1097/00000658-200301000-00005.
12. Down SK, Jha PK, Burger A, Hussien MI. Oncological advantages of oncoplastic breast-conserving surgery in treatment of early breast cancer. *Breast J.* 2013;19(1):56-63. doi: 10.1111/tbj.12047.
13. Bali R, Kankam HKN, Borkar N, Provenzano E, Agrawal A. Wide Local Excision Versus Oncoplastic Breast Surgery: Differences in Surgical Outcome for an Assumed Margin (0, 1, or 2 mm) Distance. *Clin Breast Cancer.* 2018;18(5):e1053-7. doi: 10.1016/j.clbc.2018.06.004.
14. Chu CK, Hanson SE, Hwang RF, Wu LC. Oncoplastic partial breast reconstruction: concepts and techniques. *Gland Surg.* 2021;10(1):398-410. doi: 10.21037/gs-20-380.
15. Patel K, Bloom J, Nardello S, Cohen S, Reiland J, Chatterjee A. An Oncoplastic Surgery Primer: Common Indications, Techniques, and Complications in Level 1 and 2 Volume Displacement Oncoplastic Surgery. *Ann Surg Oncol.* 2019;26(10):3063-70. doi: 10.1245/s10434-019-07592-5.
16. Weber WP, Morrow M, Boniface J, Pusic A, Montagna G, Kappos EA, et al. Knowledge gaps in oncoplastic breast surgery. *Lancet Oncol.* 2020;21(8):e375-85. doi: 10.1016/S1470-2045(20)30084-X.
17. Kollias J, Davies G, Bochner MA, Gill PG. Clinical impact of oncoplastic surgery in a specialist breast practice. *ANZ J Surg.* 2008;78(4):269-72. doi: 10.1111/j.1445-2197.2008.04435.x.
18. Urban C, Lima R, Schunemann E, Spautz C, Rabinovich I, Anselmi K. Oncoplastic principles in breast conserving surgery. *Breast.* 201;20(3):92-5. doi: 10.1016/S0960-9776(11)70302-2.
19. Bordoni D, Cadenelli P, Ornelli M, Falco G, Accurso A, Gloria A, et al. The axillary flap in oncoplastic resection of breast cancers located in the upper-outer quadrants: a new surgical technique. *BMC Surg.* 2019;18(1):21. doi: 10.1186/s12893-018-0467-3.
20. Sakina Abidi S, Mushtaque Vohra L, Rizwan Javed M, Khan N. Oncoplastic surgery: A suitable alternative to conventional breast conserving surgery in low - Middle income countries; a retrospective cohort study. *Ann Med Surg (Lond).* 202;68:102618. doi: 10.1016/j.amsu.2021.102618.
21. Albasri AM, Ansari IA, Aljohani AR, Alhujaily AS. Granular cell tumour of the breast in a young female: A case report and literature review. *Niger J Clin Pract.* 2019;22(5):742-4. doi: 10.4103/njcp.njcp_282_18.
22. Bertozzi N, Pesce M, Santi PL, Raposio E. Oncoplastic breast surgery: comprehensive review. *Eur Rev Med Pharmacol Sci.* 2017;21(11):2572-85.
23. Shin ES, Kim HI, Song SY, Lew DH, Lee DW. Selection of oncoplastic surgical technique in Asian breast cancer patients. *Arch Plast Surg.* 2018;45(1):37-44. doi: 10.5999/aps.2017.00836.
24. Lee S, Jung Y, Bae Y. Dermoglandular rotation flap with subaxillary advancement flap as an oncoplastic technique for breast cancer. *Breast J.* 2020;26(3):420-6. doi: 10.1111/tbj.13503.
25. Weber WP, Soysal SD, Fulco I, Barandun M, Babst D, Kalbermatten D, et al. Standardization of oncoplastic breast conserving surgery. *Eur J Surg Oncol.* 2017;43(7):1236-43. doi: 10.1016/j.ejso.2017.01.006.
26. Clough KB, Kaufman GJ, Nos C, Buccimazza I, Sarfati IM. Improving breast cancer surgery: a classification and quadrant per quadrant atlas for oncoplastic surgery. *Ann Surg Oncol.* 2010;17(5):1375-91. doi: 10.1245/s10434-009-0792-y.

Стаття надійшла до редакції 28.10.2022. – Дата першого рішення 04.11.2022. – Стаття подана до друку 14.12.2022