

Combined staged surgical hemostasis in a case of Placenta previa and Placenta accreta spectrum disorders

O. V. Golyanovskiy¹, D. V. Kulchytskyi², A. M. Rubinshtein¹

¹Shupyk National Healthcare University of Ukraine, Kyiv

²Kyiv City Oleksandrivska Clinical Hospital

The objective: to develop the optimal delivery algorithm in persons with Placenta previa alone and with partial Placenta accreta, using innovative technologies with the priority of organ-saving operations.

Materials and methods. 106 pregnant women with prenatal diagnosis of Placenta previa and the possibility of the safe pregnancy prolongation till 34-36 weeks of gestation were included in the study. To achieve the aim of the study, two groups were formed: the first (control) group – 75 patients were delivered via standard elective cesarean section in terms of 34-36 weeks; the second (main) group – 51 patients delivered in the same terms via our organ-saving method (elective cesarean section using argon-plasma tissue coagulation, agonists of oxytocin and vasopressors; and ligation of main uterine vessels and internal iliac arteries).

The following characteristics of cesarean section were taken into account: time of the fetal extraction, duration of the operation, intraoperative blood loss volume and Placenta accreta spectrum disorders (PAS) complications were compared in groups with further statistical data analysis.

Results. The mean indices of the cesarean section duration and time from the start of an operation till the fetal extraction were significantly lower ($p < 0.05$) in the second group and amounted 55.7 ± 5.1 min and 195.0 ± 21.0 sec, respectively, versus 74.5 ± 4.3 min and 274.0 ± 17.0 sec in the first group. Intraoperative blood loss volume was also significantly lower in the second group than in the first one – 775.0 ± 60.0 ml versus 970.0 ± 55.0 ml, $p < 0.05$).

The part of Placenta previa and PAS combination in one patient amounted to 20.0% in the first group and 17.6% in the second one. Pl. accreta was diagnosed in 17.33% cases in the first group, Pl. increta – in 1.33%, Pl. percreta – in 1.33%. Hysterectomy has been performed in 8.0% cases, all Pl. increta and percreta cases required the hysterectomy and were followed by massive obstetric hemorrhages (MOH). DIC-syndrome developed in 2.67%. In the second group Pl. accreta was diagnosed in 19.61% and Pl. increta – in 3.92%, patients with Pl. increta had hysterectomy.

MOH were observed in 38.7% cases in the first group versus 9.7% cases in the second group ($p < 0.05$). Furthermore, in the first group hysterectomy was performed almost four times more frequently than in the second group (24.0% versus 6.5% respectively, $p < 0.05$).

Conclusions. The developed delivery algorithm in pregnant women with Placenta previa alone or in a combination with PAS allowed to reduce intraoperative blood loss significantly, prevent the MOH development, therefore to reach secure hemostasis and save the uterus.

Keywords: massive obstetric hemorrhage, placenta previa, placenta accreta spectrum, uterine vessels ligation, cesarean section, hysterectomy.

Комбінований поетапний хірургічний гемостаз у випадку Placenta previa та Placenta accreta О.В. Голяновський, Д.В. Кульчицький, А.М. Рубінштейн

Мета дослідження: розроблення оптимального алгоритму розродження жінок з Placenta previa як окремої патології або у комбінації з частковою Placenta accreta з використанням інноваційних технологій та пріоритетом органозберігальних операцій.

Матеріали та методи. У дослідженні взяли участь 106 вагітних із діагнозом передлежання плаценти та можливістю безпечного пролонгування вагітності до 34–36 тиж гестації. Для досягнення мети дослідження було сформовано дві групи: перша група (контрольна) – 75 пацієток, розроджених шляхом стандартного елективного кесарева розтину у терміні 34–36 тиж; друга група (основна) – 51 пацієтка, розроджена у ті самі терміни згідно з розробленим органозберігальним алгоритмом (елективний кесарів розтин з використанням аргоноплазмової коагуляції тканин, агоністів окситоцину та вазопресорів, перев'язка магістральних судин матки та внутрішніх здухвинних артерій).

Ураховували наступні характеристики кесарева розтину: час до вилучення плода, тривалість операції, обсяг інтраопераційної крововтрати та ускладнення патологій спектра Placenta accreta (PAS) порівнювали у групах з подальшим статистичним аналізом даних.

Результати. Середні значення тривалості кесарева розтину та часу від початку операції до вилучення плода були достовірно нижчими ($p < 0,05$) у другій групі і становили $55,7 \pm 5,1$ хв та $195,0 \pm 21,0$ с проти $74,5 \pm 4,3$ хв та $274,0 \pm 17,0$ с у першій групі. Обсяг інтраопераційної крововтрати також був значно нижчий у другій групі, ніж у першій, – $775,0 \pm 60,0$ мл проти $970,0 \pm 55,0$ мл ($p < 0,05$).

Частота поєднання Placenta previa та PAS в однієї пацієнтки становила 20,0% у першій групі та 17,6% у другій. У першій групі Pl. accreta була діагностована у 17,33% випадків, Pl. increta – в 1,33%, Pl. percreta – в 1,33%. Гістеректомія виконана у 8,0% випадків, усі випадки Pl. increta і percreta закінчились гістеректомією та супроводжувалися масивною акушерською кровотечею (МАК). ДВС-синдром розвинувся у 2,67% випадків. У другій групі Pl. accreta була діагностована у 19,61% випадків, а Pl. increta – у 3,92%, пацієнткам із Pl. increta знадобилася гістеректомія.

МАК спостерігали у 38,7% випадків у першій групі проти 9,7% випадків у другій групі ($p < 0,05$). Крім того, у першій групі гістеректомію проводили майже вчетверо частіше, ніж у другій (24,0% проти 6,5% відповідно; $p < 0,05$).

Висновки. Розроблений алгоритм ведення пологів при передлежанні плаценти у поєднанні з PAS дозволяє значно знизити інтраопераційну крововтрату, запобігти розвитку МАК, досягти надійного гемостазу та зберегти матку.

Ключові слова: масивна акушерська кровотеча, Placenta previa, Placenta accreta spectrum, перев'язка маткових судин, кесарів розтин, гістеректомія.

Massive obstetric hemorrhages (MOH) remain the main cause of maternal morbidity and mortality. About 9–14 million MOH cases are annually registered all over the world; about 100,000 lead to maternal mortality [1]. Massive obstetric hemorrhage can be defined as a blood loss of more than 1,500 ml, a reduction in hemoglobin of more than 40 g/L or a transfusion of 4 or more units of red blood cells [2].

One of the main MOH risk factors remains Placenta accreta spectrum disorders (PAS) causing 1 to 2% of MOH cases. The PAS frequency has increased worldwide by an order over the last 20 years and nowadays has reached 9.3–10% in a combination with Placenta previa and 0.004% in pregnant women without Placenta previa [3–6].

The history of previous C-section quite frequently becomes the reason of the decidual membrane's defect, therefore the increase of PAS rate has been connected with the increase of operative deliveries' number [7]. Clark et al. proved that for women with diagnosed Placenta previa, the risk of Placenta accreta increased from 5% (without C-section history) to 24% (with one C-section in the anamnesis) and to 67% in a case of four and more intrauterine operations [8]. D.A. Miller confirmed the correlation coherence between frequency of Placenta previa in a combination with Placenta accreta and the amount of C-sections in the anamnesis [9]. Also, the correlation between PAS rates and reduction of the time interval between C-section deliveries was proved to exist [10, 11].

A key factor of PAS management is the prenatal diagnosis. Prenatal diagnosis of PAS is challenging but feasible if the ultrasonographer is searching actively for the ultrasonic signs. Finberg H.J. and Williams J.W. diagnosed Placenta accreta in 14 out of 18 patients using the following US-markers:

- loss of normal hypoechoic retroplacental line;
- thinning of the border between the uterus and the bladder;
- the presence of multiple placental lacunae [12–15].

Sometimes, in a case of lateral or back placental localization, visualizing the pathology on the ultrasound becomes challenging, that's why some authors recommend using the MRI with the magnetic contrast in such cases [15–18].

The primary aim of PAS complications treatment is achieving fast and continuous hemostasis. It's worth noting that hemorrhages associated with Placenta previa and PAS tend to occur unexpectedly, lead to MOH and quite frequently are complicated by coagulopathic disorders. Traditionally, hysterectomy remains the

main method of surgical hemostasis in these cases, leading to decrease of life quality, infertility and other complications [19–21].

Several authors suggest performing bilateral ligation of main uterine vessels and internal iliac arteries prior to the hysterectomy, which reduces intraoperative blood loss [22–24]. Some authors have marked the possibility of an organ-saving operation in a case of Pl. accreta combined with Placenta previa using uterine arteries' embolization and following weekly administration of Methotrexate [25, 26].

The improvement of traditional C-section method, especially in case of PAS and uterine atony, invention of radiowave surgery technology and modern drugs as uterotonics and vasopressors allow obstetricians to reduce the frequency of MOH and other postoperative complications.

The method of radiowave surgery, argon-plasma tissues coagulation has been recently successfully applied for these issues in obstetric practice. The acting principle are based on the use of high frequency electromagnetic field energy, which influences on a tissue in a non-impact way via ionized argon gas at a temperature of 120 degrees to a maximal depth of three millimeters. The undoubted advantages of the method are quick and complete hemostasis on a large area; antiseptic effect; decrease of the tissue's infiltration; no electrode contact with a tissue, which eliminates the microbial contamination and charring of tissues. Deep heating of myometrium in the applied area activates reparative processes, leading to contraction of collagen fibers, which provides the additional hemostatic effect and prevents the formation of wound exudates [27, 28]. Such effects explain the possibility of argon-plasma coagulation use for the debridement of a placental bed in a case of partial Placenta accreta.

Advantages of prophylactic Carbetocin use are the fast and strong uterotonic effect (eight-ten times stronger than Oxytocin), long-lasting effect aimed at the myometrium contraction (up to two hours), and low frequency of side effects [2, 4, 5].

Terlipressin – is the angiotonic hemostatic drug. Like vasopressin it increases tonus of the vascular wall smooth muscles and this way causes the constriction of arterioles, veins, venules. It stimulates myometrium activity independently from pregnancy, and in a case of topical administration [2].

Such complex approach to the hemostasis in cases of Placenta previa and PAS, allows preventing the development of massive blood loss and hysterectomy.

The aim of the work was to develop the optimal delivery algorithm in a case of Placenta previa alone and with partial Placenta accreta, using innovative technologies to the priority of organ-saving operations.

MATERIALS AND METHODS

The case-control study was carried out in two stages. On the first stage we conducted the retrospective analysis of 75 cases (the I-st or control group) of the planned C-section in pregnant women with prenatally diagnosed Placenta previa in terms of 34-36 weeks; on the second stage we conducted a prospective dynamic research of 51 planned operative delivery (the II-nd or main group) with Placenta previa in the same pregnancy terms via the organ-saving algorithm (C-section with the use of agonists of oxytocin and vasopressors, argon-plasma tissue coagulation and ligation of main uterine vessels).

Inclusion criteria were prenatally diagnosed Placenta previa and the possibility of the safe pregnancy prolongation till the optimal term for elective C-section (34–36 weeks).

Indications for surgical hemostasis in both groups were PAS and MOH. Blood loss was measured by the gravimetric method and clinically – by the Allover shock index.

The algorithm of an operative delivery in a case of Placenta previa with Placenta accreta consisted of the following stages:

1. Laparotomy by the monopolar radiowave scalpel in order to provide additional hemostasis and decrease the infectious-inflammatory complications (Fig. 1.).
2. IV administration of 100 mcg of Carbetocin after the cord clumping (10 IU of Oxytocin were administered in the first group). Placenta was delivered using controlled traction to the umbilical cord.
3. In case of following continuing hemorrhage from a placental bed:
 - administration of 0.4 mg of Terlipressin with isotonic solution of NaCl into the lower uterine segment;
 - tamponade of a uterine cavity by a gauze napkin, moistened in the solution of 5% aminocaproic acid (Fig. 2.).
4. Staged partial uterine devascularization:
 - in a case of continuing hemorrhage from the placental bed and cervix bilateral ligation of the descending branches of the uterine arteries (Fig. 3);
 - bilateral ligation of the ovarian vessels (Fig. 4);
 - bilateral internal iliac arteries ligation (Fig. 5) – rarely in case of clinical manifestations of hemorrhagic shock and uterine atony.

Taking into account the MOH possibility, in the second group we performed bilateral internal iliac arteries li-

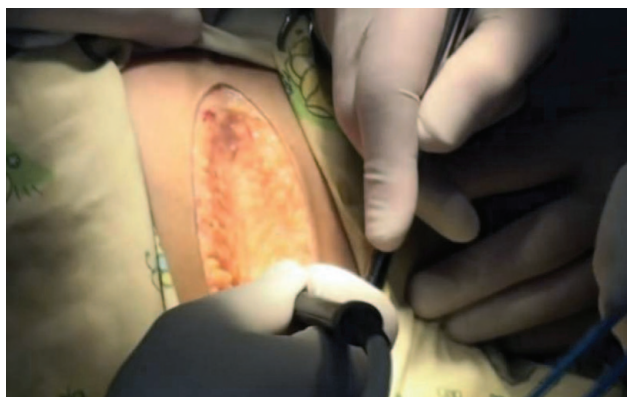

Figure 1. Lower middle laparotomy with the monopolar radiowave scalpel

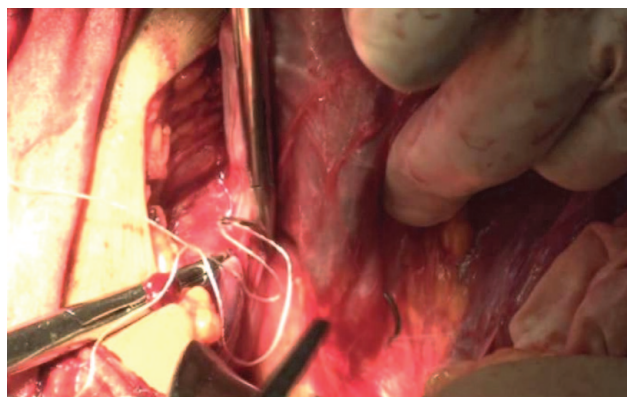


Figure 3. Ligation of the uterine arteries

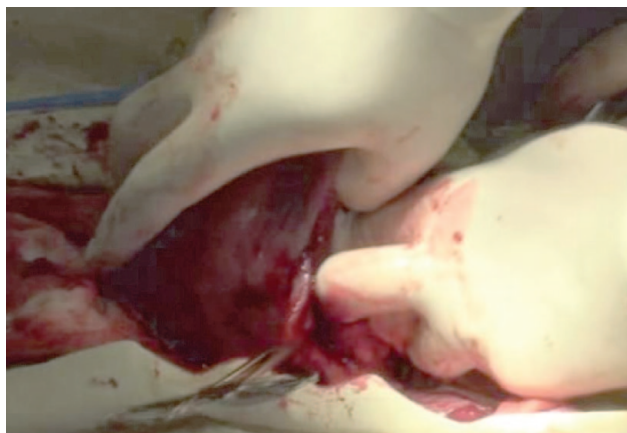


Figure 2. A tamponade of the uterine cavity by a gauze napkin

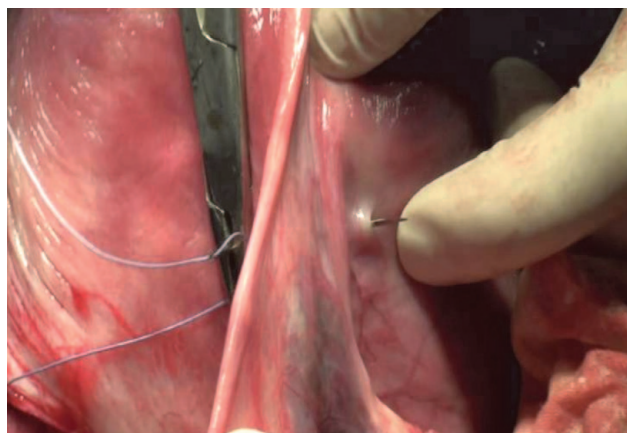


Figure 4. Ligation of the ovarian vessels

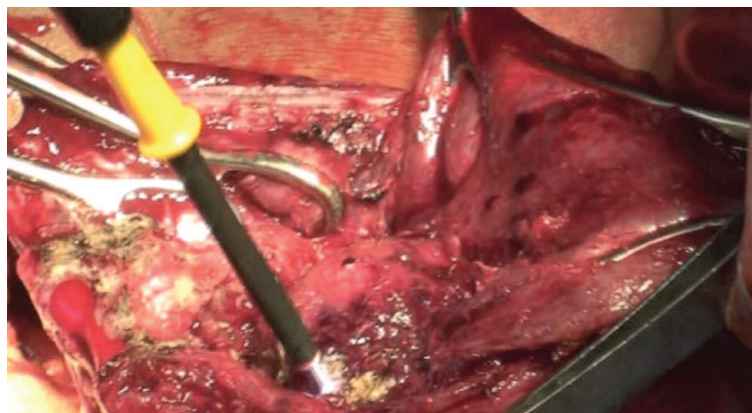
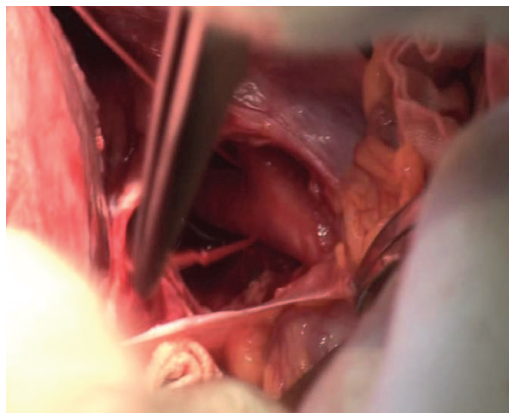


Figure 5. Ligation of the internal iliac arteries

Figure 6. Argon-plasma coagulation of a Placental bed

gation on the first level (1-1,5 cm below the bifurcation of the common iliac artery) before the hysterectomy in case of diagnosed PAS to reduce intraoperative blood loss and prevent the hemorrhagic shock.

5. The placental bed (Fig. 6), uterotomic area and anterior abdominal wall tissues were coagulated by the argon-plasma torch.

The postpartum uterine involution rates were estimated by ultrasound on the fourth day after a C-section. Traditional uterine parameters (the length, width, front-back size, and the width of the uterine cavity) and the presence of ultrasonic signs of increments in the area of postoperative sutures were measured.

The statistical processing of received data was conducted by a method of the variation statistic with the use of Student t-test for the determination of the reliability of the difference of averages. Comparison of samples that contained qualitative features was conducted by the exact Fischer's criterion.

RESULTS AND DISCUSSION

Groups were comparable by social status, age, parities, somatic health, amount of conducted investigations, monitoring and time of investigations. The age of women varied within the limits of 21–39 years in both groups. Most of the women had a history of the C-section delivery (66.67% in the first group and 70.59% in the second). The obtained results indirectly prove the association between a previous C-section and PAS development. Four pregnant women with a twin pregnancy were in the first group and one with dichorionic twins – in the second.

In the first group the number of pregnant women with complete Placenta previa was 66.67% and 33.33% had incomplete one, against 74.51% and 25.49% respectively in the second group; differences of this parameter value was not observed.

All pregnant women were delivered by C-section. In cases of Placenta previa preferably localized on the anterior wall (40.0% and 41.18% respectively), a corporal C-section above the Placental margin was performed in the first group, apart from the second, where we have performed the fundal C-section. In other cases C-section by Stark was performed in the lower uterine segment.

Means of the C-section duration and time from the start of an operation till the fetal extraction were authentically lower ($p < 0.05$) in the second group and amounted 55.7 ± 5.1 min versus 74.5 ± 4.3 min in the first group and 195.0 ± 21.0 sec versus 274.0 ± 17.0 sec in the first group (Table 1). Intraoperative blood loss volume was also significantly lower in the second group (970.0 ± 55.0 ml versus 775.0 ± 60.0 ml, $p < 0.05$).

These results we have connected with the use of argon-plasma tissue's coagulation, which gave the possibility to perform fast and secure additional hemostasis; administration of modern uterotonics and vasopressors that shows higher effectiveness then their traditional analogs. Taking into account the difficulty of placental margin determination, the performance of

Table 1

Parameters of a Caesarian section in the studied groups (M±m)

Index	First group, $n_1=75$	Second group, $n_2=51$	p
Time till the fetal extraction (sec)	274.0±17.0	195.0±21.0	$p < 0.05$
Duration of C-section (min)	74.5±4.3	55.7±5.1	$p < 0.05$
Intraoperative blood loss (ml)	970.0±55.0	775.0±60.0	$p < 0.05$

Table 2

Complications of AIP and qualities of surgical hemostasis in the studied groups

Index	Control group, $n_1=75$		Study group, $n_2=51$		p
	Abs. numb.	%	Abs. numb.	%	
Uterine atony	13	17.33	2	3.92	$p < 0.05$
Hysterectomy	18	24.0	4	7.84	$p < 0.05$
Main uterine vessels ligation	11	14.67	10	19.61	$p > 0.05$
MOH	29	38.67	5	9.8	$p < 0.05$
DIC-syndrome	2	2.67	0	0	$p > 0.05$

US – parameters of the uterus on the fourth day after C-section in the studied groups (M±m)

Index	Control group, n ₁ =75	Study group, n ₂ =51	p
Length of the uterus (cm)	14.23±0.14	13.47±0.11	p<0.05
Width of the uterus (cm)	8.45±0.21	7.86±0.19	p<0.05
Front-back size of the uterus (cm)	13.01±0.19	11.27±0.15	p<0.05
Volume of the uterus (ml)	695.56±21.4	594.5±23.31	p<0.05

fundal C-section in a cases of anterior placental location prevented complementary blood loss from injured placenta. Staged partial uterine devascularization performed in a case of diagnosed Pl. accreta also declined intraoperative blood loss.

We also have analyzed PAS complications and particular qualities of performed surgical hemostasis in both groups (Table 2).

The part of Placenta previa and PAS combination in one patient amounted to 20.0% in the first group and 17.6% in the second one. Pl. accreta was diagnosed in 17.33% cases in the first group, Pl. increta – in 1.33%, Pl. percreta – in 1.33%; the hysterectomy has been performed in 8.0% cases, all Pl. increta and percreta cases required the hysterectomy and were followed by the MOH; the DIC-syndrome developed in 2.67%. In the second group Pl. accreta was diagnosed in 19.61% and Pl. increta – in 3.92%, patients with Pl. increta required hysterectomy.

Uterine atony and MOH developed more frequently (p<0.01) in the second group (17.33% versus 3.92% and 38.67% versus 9.8%). Also, in the first group, 2.7% cases of MOH were complicated by the DIC-syndrome. Furthermore, among the patients of the first group, the probability of hysterectomy was almost 4 times higher than in the second group (OR 3.7; CI 1.18 to 11.72; p<0.05).

In the postoperative period we have observed (ultrasound – US) authentically faster (p<0.05) uterine involution temps among patients of the second group (Table 3).

These results we connected with the uterotonic effect of Carbetocin, local vassopressive effect of Terlipressin and the complex influence of argon-plasma tissue coagulation. Despite the decrease by more than a half of the pulse index and the systolic-diastolic ratio in uterine arteries after main uterine vessels ligation, the minimal required blood flow remained in a uterus and we did not observe the necrobiotic changes after this procedure. The postoperative period passed without maternal and fetal mortality, and other complications in both groups. Duration of hospital stay after the operation was slightly higher in the first group, but did not differ significantly (9.15±2.35 days in the first group versus 7.32±2.18 days in the second).

CONCLUSIONS

1. Applying of the radiowave scalpel, argon-plasma coagulation, staged partial uterine devascularization with the use of agonists of oxytocin and vasopressors during C-section in a case of Placenta previa and in a combination with partial Pl. accreta significantly reduced intraoperative blood loss; prevented the MOH development, created secure hemostasis and allowed to save the uterus.

2. Taking into account the relatively small number of observations, it is necessary to continue studies of the effectiveness of proposed combined surgical and drug hemostasis with a technical maintenance at different clinical variants of Placenta previa and PAS.

Information about authors

Golyanovskiy Oleg V. – Doctor of Medical Sciences, Professor, Head of the Department of Obstetrics and Gynecology №1 of Shupik National Healthcare University of Ukraine, Kyiv; tel.: (044)489-35-64; (067) 741-77-68. *E-mail: golyanovskiyoleg@yahoo.com*

ORCID: 0000-0002-5524-4411

Kulchytskyi Dmytro K. – PhD, obstetrician-gynecologist, «Kyiv City Oleksandrivska Clinical Hospital»; tel: +38(093)149-13-54. *E-mail: dr.kulchytskyi86@gmail.com*

Rubinshtein Anna M. – correspondence PhD student of the Department of Obstetrics and Gynecology №1 of Shupik National Healthcare University of Ukraine, Kyiv, obstetrician-gynecologist of Maternity Hospital «Leleka», Kyiv; tel.: (044) 334-72-08; (066) 005-88-81. *E-mail: anshantar@gmail.com*

ORCID: 0000-0001-7827-9310

Відомості про авторів

Голяновський Олег Володимирович – д-р мед. наук, проф., завідувач кафедри акушерства та гінекології № 1 Національного університету охорони здоров'я України імені П.Л. Шупика, м. Київ; тел.: (044) 489-35-64; (067) 741-77-68. *E-mail: golyanovskiyoleg@yahoo.com*

ORCID: 0000-0002-5524-4411

Кульчицький Дмитро Вікторович – канд. мед. наук, акушер-гінеколог вищої кваліфікаційної категорії КНП «Олександрівська клінічна лікарня м. Києва»; тел.: (093) 149-13-54. *E-mail: dr.kulchytskyi86@gmail.com*

Рубінштейн Анна Мойсеївна – заочний аспірант кафедри акушерства та гінекології №1 Національного університету охорони здоров'я України імені П.Л. Шупика, м. Київ, акушер-гінеколог ТОВ «Пологовий будинок «Лелека», м. Київ; тел.: (044) 334-72-08; (066) 005-88-81. *E-mail: anshantar@gmail.com*

ORCID: 0000-0001-7827-9310

REFERENCES

1. GBD 2015 Disease and Injury Incidence and Prevalence Collaborators. Global, regional, and national incidence, prevalence, and years lived with disability for 310 diseases and injuries, 1990-2015: A systematic analysis for the global burden of disease study 2015. *Lancet*. 2016;388:1545-602.
2. Mavrides E, Allard S, Chandraran E, Collins P, Green L, Hunt BJ, et al. Prevention and management of postpartum haemorrhage (Green-top Guideline 52). *BJOG*. 2016;124:106-49. doi: 10.1111/1471-0528.14178.
3. Jauniaux E, Chantraine F, Silver RM, Langhoff-Roos J. FIGO consensus guidelines on placenta accreta spectrum disorders: epidemiology. *Int J Gynecol Obstet*. 2018;140(3):265-73. doi: 10.1002/ijgo.12407.
4. Shamshirsz AA, Fox KA, Salமான B, Diaz-Arrastia CR, Lee W, Baker BW, et al. Maternal morbidity in patients with morbidly adherent placenta treated with and without a standardized multidisciplinary. *Am J Obstet Gynecol*. 2015;212(2):218.e1-9. doi: 10.1016/j.ajog.2014.08.019.
5. Jauniaux E, Bhide A, Kennedy A, Woodward P, Hubinont C, Collins S, et al. FIGO consensus guidelines on placenta accreta spectrum disorders: prenatal diagnosis and screening. *Int J Gynecol Obstet*. 2018;140(3):274-80. doi: 10.1002/ijgo.12408.approach.
6. Jauniaux E, Alfirevic Z, Bhide AG, Burton GJ, Collins SL, Dornan S, et al. Placenta Praevia and Placenta Accreta: diagnosis and Management: green-top Guideline No. 27a *BJOG*. *Int J Obstet Gynaecol*. 2019;126(1):1-48. doi: 10.1111/1471-0528.15306.
7. Silver RM, Branch DW, Solomon CG. Placenta Accreta Spectrum. *N Engl J Med*. 2018;378(16):1529-36. doi: 10.1056/NEJMcp1709324.
8. Clark SL, Koonings PP, Phelan JP. Placenta previa/accreta and prior cesarean section. *Obstet Gynecol*. 1985;66(1):89-92.
9. Miller DA, Cholleet JA, Goodwin TM. Clinical risk factors for Placenta previa-Placenta accreta. *Am J Obstet Gynecol*. 1997;177:210-14. doi: 10.1371/journal.pone.0052893.
10. Jauniaux E, Bhide A. Prenatal ultrasound diagnosis and outcome of placenta previa accreta after cesarean delivery: a systematic review and meta-analysis. *Am J Obstet Gynecol*. 2017;217(1):27-36. doi: 10.1016/j.ajog.2017.02.050
11. Wax JR, Seiler A, Horowitz S, Ingardia CJ. Interpregnancy interval as a risk factor for Placenta accreta. *Conn Med*. 2000;64(11):659-61.
12. Jauniaux E, Collins S, Burton GJ. Placenta accreta spectrum: pathophysiology and evidence-based anatomy for prenatal ultrasound imaging. *Am J Obstet Gynecol*. 2018;218(1):75-87. doi: 10.1016/j.ajog.2017.05.067.
13. Jauniaux E, Collins SL, Jurkovic D, Burton GJ. Accreta placentation: a systematic review of prenatal ultrasound imaging and grading of villous invasiveness. *Am J Obstet Gynecol*. 2016;215(6):712-21. doi: 10.1016/j.ajog.2016.07.044.
14. Collins SL, Ashcroft A, Braun T, et al. Proposal for standardized ultrasound descriptors of abnormally invasive placenta (AIP). *Ultrasound Obstet Gynecol off J Int Soc Ultrasound Obstet Gynecol*. 2016;47(3):271-75. doi: 10.1016/j.ajog.2018.03.013.
15. Einerson BD, Rodriguez CE, Kennedy AM, Woodward PJ, Donnelly MA, Silver RM. Magnetic resonance imaging is often misleading when used as an adjunct to ultrasound in the management of placenta accreta spectrum disorders. *Am J Obstet Gynecol*. 2018;218(6):618.e1. doi: 10.1016/j.ajog.2018.03.013.
16. Familiari A, Liberati M, Lim P, Pagani G, Cali G, Buca D, et al. Diagnostic accuracy of magnetic resonance imaging in detecting the severity of abnormal invasive placenta: a systematic review and meta-analysis. *Acta Obstet Gynecol Scand*. 2018;97(5):507-20. doi: 10.1111/aogs.13258.
17. Einerson BD, Rodriguez CE, Kennedy AM, Woodward PJ, Donnelly MA, Silver RM. Magnetic resonance imaging is often misleading when used as an adjunct to ultrasound in the management of placenta accreta spectrum disorders. *Am J Obstet Gynecol*. 2018;218(6):618.e1. doi: 10.1016/j.ajog.2018.03.013.
18. Morel O, Collins SL, Uzan-Augui J, Masselli G, Duan J, Chabot-Lecoanet A-C, et al. A proposal for standardized magnetic resonance imaging (MRI) descriptors of abnormally invasive placenta (AIP) - From the International Society for AIP. *Diagn Interv Imaging*. 2019;100(6):319-25. doi: 10.1016/j.diii.2019.02.004.
19. Jauniaux E, Hussein AM, Fox KA, Collins SL. New evidence-based diagnostic and management strategies for placenta accreta spectrum disorders. *Best Pract Res Clin Obstet Gynaecol*. 2019;61:75-88. doi: 10.1016/j.bpobgyn.2019.04.006.
20. Jauniaux E, Ayres-de-Campos D, Langhoff-Roos J, Fox KA, Collins S. FIGO Duncombe FIGO classification for the clinical diagnosis of placenta accreta spectrum disorders. *Int J Gynaecol Obstet off Organ Int Fed Gynaecol Obstet*. 2019;146(1):20-4. doi: 10.1002/ijgo.12761.
21. Collins SL, Alemdar B, Van Beekhuizen HJ, Bertholdt C, Thorsten B, Calda P, et al. Evidence-based guidelines for the management of abnormally invasive placenta: recommendations from the International Society for Abnormally Invasive Placenta. *Am J Obstet Gynecol*. 2019;220(6):511-26.
22. Mahajan NN, Gaikwad NL, Mahajan KN, Soni RN. Internal iliac artery ligation for arresting postpartum haemorrhage. *BJOG*. 2007;114(7):906. doi: 10.1111/j.1471-0528.2007.01360.x.
23. Dohbit JS, Foumane P, Nkwabong E, Kamouko CO, Tochie JN, Otabela B, et al. Uterus preserving surgery versus hysterectomy in the treatment of refractory postpartum haemorrhage in two tertiary maternity units in Cameroon: a cohort analysis of perioperative outcomes. *BMC Pregnancy Childbirth*. 2017;17(1):158. doi: 10.1186/s12884-017-1346-0.
24. Bouet PE, Madar H, Froeliger A, El Hachem H, Schinkel E, Mattuizi A, et al. Surgical treatment of postpartum haemorrhage: national survey of French residents of obstetrics and gynecology. *BMC Pregnancy Childbirth*. 2019;19(1):91. doi: 10.1186/s12884-019-2237-3.
25. Chou M-M, Yuan J-C, Lu Y-A, Chuang S-W. Successful treatment of placenta accreta spectrum disorder using management strategy of serial uterine artery embolization combined with standard weekly and a 8-day methotrexate/folinic acid regimens at 7 weeks of gestation. *Taiwanese J Obstet Gynecol*. 2020;59(6):952-5. doi:10.1016/j.tjog.2020.09.027.
26. Gregoir C, Becker BD, Hauspy J, Van derheyden T, Loquet P. The use of methotrexate in conservative treatment of placenta accreta spectrum disorders. *J Matern Fetal Neonatal Med*. 2021;18:1-4. doi: 10.1080/14767058.2021.1951211.
27. Olmos JA, Marcolongo M, Pogorelsky V, Varela E, D volos JR. Argon plasma coagulation for prevention of recurrent bleeding from GI angiodysplasias. *Gastrointest Endosc*. 2004;60:881-6. doi: 10.1016/s0016-5107(04)02221-7.
28. Manner H. Argon plasma coagulation therapy. *Curr Opin Gastroenterol*. 2008;24:612-6. doi: 10.1097/MOG.0b013e32830bf825.

Стаття надійшла до редакції 07.06.2022. – Дата першого рішення 14.06.2022. – Стаття подана до друку 19.07.2022